

## HORMONE RECEPTOR EXPRESSION IN MALE BREAST CANCERS

\*A.B. AKOSA, S. VAN NORDEN<sup>1</sup> AND Y. TETTEY

Department of Pathology, University of Ghana Medical School, Accra, Ghana and <sup>1</sup>Histopathology, Imperial College of Science, Technology and Medicine, Hammersmith Hospital, London.

### SUMMARY

Male breast cancers are rare but have been found in higher proportions in Black Africans. Prognostic factors for breast cancers include tumour size, grade and stage, and hormone receptor status. The hormone receptor status is an invaluable guide in the use of adjuvant endocrine therapy, but none of the reports available in the literature from Africa showed any receptor work.

This study was conducted to determine the grade, lymph node status and hormone receptor status of male breast cancers in Ghana.

Nine archival cases of male breast cancers from the Pathology Department of Korle Bu Teaching Hospital were selected and studied on the basis of the presence of enough material for immunocytochemistry. Haematoxylin and Eosin (H & E) stained slides were reviewed and graded by Bloom and Richardson's criteria. Lymph node status was also assessed and sections were stained for oestrogen and progesterone receptors.

Seven of the nine tumours were invasive ductal carcinomas and six of these were grade II, and one was grade III. Four cases had axillary lymph nodes removed at surgery and three were positive for metastases. Six (66%) of the cases were positive for oestrogen receptors with an H score ranging from 20 to 300. Using the criteria of McCarty et al, positivity for oestrogen receptor was reduced to 44%, which is lower than for Caucasians. We believe that this may be explained by the fact that in Ghana male breast cancers are seen a decade earlier. Only two cases were positive for progesterone receptor with an H score of 10 and 75. The two cases positive for progesterone receptors were also positive for oestrogen receptors.

It is concluded that hormone receptor study is important in deciding on endocrine and adjuvant chemotherapy in male breast cancers and should be done routinely to help surgeons plan postoperative management of these patients. We recommend further research in this area.

**Keywords:** Cancer, breast cancer, male breast cancer, cancer prognostic indices, oestrogen receptor, progesterone receptor.

### INTRODUCTION

Male breast cancers are rare but have been found in higher proportions in Black Africans<sup>1,2</sup>.

In a retrospective study of breast cancers in Ghana (1980-1996) there were 18 male and 735 female breast cancers<sup>3</sup>. Thus in Ghana, 2.4% of breast cancers are in males compared to less than 1% in Caucasians<sup>3</sup>. The ages of the 18 males with breast cancer ranged from 30 to 79 years with a mean of 48.5 years. The mean age at presentation was a decade latter than female breast cancers in Ghana but not more than a decade earlier than for breast cancers in Caucasian population<sup>3</sup>.

Some prognostic factors for breast cancers include tumour size, grade and stage, and hormone receptor status. The hormone receptor status is an invaluable guide in the use of endocrine therapy and therefore the absence of such a useful index affects the management of breast cancers. None of the reports from Africa discussed in the initial study<sup>3</sup> studied hormone receptor expression.

This study was conducted to determine the grade and lymph node status and to semi-quantify hormone receptor status of male breast cancers in Ghana.

---

\* Author for correspondence

## METHOD

Nine of the 18 archival cases of male breast cancers (1980-1996) from the Pathology Department of the Korle Bu Teaching Hospital were selected for the immunocytochemistry study based on the presence of enough cellular material. Cases that did not have enough comparable cellular material were discarded.

The original Haematoxylin and Eosin (H & E) stained slides were reviewed by two of the authors and the tumour grade established using Bloom and Richardson's criteria<sup>4</sup>. Four of the cases selected for immunocytochemistry study also had paraffin blocks of axillary lymph nodes and these were also retrieved. All the selected cases and lymph nodes were sent to the second author for immunocytochemistry.

### Protocol for immunostaining for oestrogen and progesterone receptors

Paraffin sections of the cases were cut at 2 microns and mounted on "polysine" charged slides (Merck Ltd.) for good sections adhesion. The slides were dried overnight at 37°C, dewaxed through xylene and graded alcohols to water.

The sections were blocked for endogenous peroxidase by immersion for 30 minutes in 0.3% hydrogen peroxide in water and then rinsed in water.

### Antigen retrieval

Sections were immersed in 0.01M citrate buffer at pH 6 overnight at 80°C. Most of the tissue stayed on the slides, and what came off was fatty areas rather than tumour. The sections were rinsed in water then phosphate buffered saline (PBS) and positioned against Sequenza (Shandon Life Sciences) coverplates and placed in Sequenza racks.

### Background blocking

Non-specific binding was blocked for ten minutes by treating the slides with non-immune swine or goat serum at 1/20 dilution in 0.01M phosphate-buffered saline at pH of 7.2 (PBS) containing 0.1% bovine serum albumin and 0.1% sodium azide (antibody diluent). After a brief rinse with PBS, endogenous avidin and biotin were blocked by application of avidin to the tissue sections for 15 minutes followed, after rinsing, by biotin for 15 minutes (Vector Laboratories biotin blocking kit) and rinsed again.

### Primary antibody

The sections were incubated overnight at 4°C in rabbit anti-progesterone receptor (Dako Limited,

Cat. No. A0098) diluted at 1/400 or monoclonal mouse anti-oestrogen receptor (Novocastra, cat. No. NCL-ER-6F11) diluted at 1/300 in antibody diluent. Two negative control sections were provided from each block.

For the rabbit anti-progesterone receptor assay specimen were incubated in non-immune rabbit serum diluted at 1/2000 and for the monoclonal anti-oestrogen receptor, the specimen were incubated in antibody diluent. Positive controls consisted of a section of uterus, known to be positive for the progesterone receptor and a section of a breast carcinoma known to be positive for the oestrogen receptor.

### Second and third reagent

Following a five minute rinse in PBS the sections that had been exposed to the rabbit anti-progesterone or the non-immune rabbit serum were incubated for 30 minutes at room temperature in biotinylated swine anti-rabbit immunoglobulin (Dako Limited, Cat No. E0353) while the remaining sections were incubated in biotinylated goat anti-mouse immunoglobulin (Dako, Limited Cat No. E0433). Both antibodies were diluted at 1/500 in PBS antibody diluent.

After a further five minutes rinse in PBS, peroxidase-labelled streptavidin (Boehringer Mannheim, Cat No. 1089 153) was applied for 30 minutes at a dilution of 1/500 in protoxidase that are linked to peroxidase.

### Development of peroxidase

After rinsing, the peroxidase was revealed by incubation of the sections for 10 minutes in 0.05% diaminobenzidine tetrahydrochloride (DAB) (Sigma, Cat. No D5637) in PBS containing 0.01% hydrogen peroxide.

The nuclei were lightly stained in haematoxylin, and the sections were dehydrated through graded alcohols, cleared in xylene and mounted in a synthetic mountant.

The intensity of staining was assessed independently by all 3 authors and the proportion of cells positive was also assessed independently by two of the authors. The intensity was graded on a 4 point scale (0) negative, 1(+) weak, 2(++) moderate and 3(+++) strong.

## RESULTS

Seven of the nine tumours were invasive ductal carcinomas and six of the seven (6/7) were grade II

(moderately differentiated) and one (1/7) was a grade III (poorly differentiated) carcinoma. The two other tumours were one each of mucinous and lobular carcinomas. Table 1 shows histological diagnosis, grade and lymph node status of the 9 male breast cancers.

The two cases that were positive for progesterone receptor were also positive for oestrogen receptors. There were no progesterone receptor positive and oestrogen receptor negative tumours. Table 2 shows hormone receptor status of male breast cancers.

**Table 1** Histological diagnosis, grade and lymph node status of 9 male breast cancers.

No	Age	Diagnosis	Grade	Lymph node status
1	50	Invasive ductal carcinoma	II	No lymph nodes (lumpectomy)
2	52	Invasive ductal carcinoma	II	Positive lymph nodes
3	48	Invasive ductal carcinoma	III	No lymph nodes (lumpectomy)
4	65	Invasive ductal carcinoma	II	Positive lymph nodes
5	32	Invasive ductal carcinoma	II	No lymph nodes (lumpectomy)
6	54	Mucinous/Mucoid carcinoma		Negative lymph nodes
7	NS	Lobular carcinoma and LCIS		No lymph nodes (lumpectomy)
8	44	Invasive ductal carcinoma	II	Positive lymph node
9	79	Invasive ductal carcinoma	II	No lymph nodes (lumpectomy)

NS-not stated

**Table 2** Hormone status of male breast cancer

Case	Oestrogen receptor			Progesterone receptor		
	Intensity	Proportion of cells %	Staining index	Intensity	Proportion of cells %	Staining index
IDC	-	-	0	-	-	0
IDC	-	-	0	-	-	0
IDC	2	80	160	-	-	0
IDC	-	-	0	-	-	0
IDC	2	25	50	-	-	0
Mucinous Ca	2	20	20	-	-	0
Lobular Ca	3	100	300	3	25	75
IDC	2	70	140	2	5	10
IDC	3	10	30	-	-	0

Staining positive

H score/staining index positive

IDC – Invasive Ductal Carcinoma

6/9 = 66%

4/9 = 44%

Staining positive

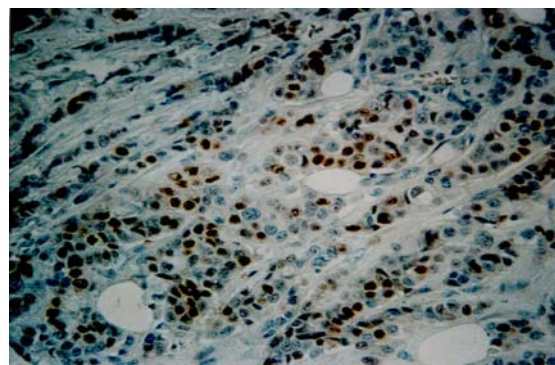
H score/staining index positive

2/9 = 22%

1/9 = 11%

Five of the nine cases had lumpectomies with no lymph node removal. A search through the histopathology files did not reveal subsequent lymph node removals. Four cases had axillary lymph nodes removed at surgery and three were positive for metastasis.

Immunocytochemical staining for oestrogen receptor showed 6 positive with moderate and strong staining intensity (Figure 1). The proportion of positive cells ranged from 10-100% and the staining index or H score<sup>5,6</sup> ranged from 20-300. Using MacCarty et al<sup>5</sup> proposed H score of 50 as positive, the percentage positivity reduced from 66% to 44%. Progesterone receptor status revealed two positives with an H score of 10 and 75.



**Figure 1** Immunocytochemical stain for oestrogen receptor showing strong staining (80% positive cells) in a case of invasive ductal carcinoma (x40)

## DISCUSSION

Early studies on male breast cancer reported a poorer prognosis compared to breast cancer in females due to the proximity of the male breast cancer to the chest wall, with shorter lymphatics draining into the internal mammary nodes and allowing rapid dissemination of tumour. It was also attributed to the closeness to skin with frequent ulceration and inflammation leading to increased lymphatic flow and tumour spread<sup>7</sup>. Poorer survivals were also in part aggravated by diagnostic delays and the older age of the patients<sup>8</sup>. Other workers suggested an innate difference in biological aggressiveness of the male tumour<sup>9,10</sup>.

Careful studies however, have shown no poorer outlook in men and no prognostic differences between male and female patients with comparable disease<sup>11</sup>.

Seven of the nine cases were invasive ductal carcinoma and 87% (6/7) were grade II (moderately differentiated carcinomas). In the series of Ihek-waba<sup>12</sup>, 18%, 33%, and 49% were well differentiated, moderately differentiated and poorly differentiated carcinomas respectively and 70% of cases were poorly differentiated in the series by Jamal et al<sup>13</sup>.

Tumours of the male breast show a greater positivity of oestrogen and progesterone receptors than tumour of the female breast and varies from 65-100% for oestrogen receptors and 50-75% for progesterone receptors<sup>14,15,16,17,18</sup>.

The high positive staining for oestrogen receptors in males compared to females has been attributed to development in minimal exposure to endogenous oestrogens and therefore likened to postmenopausal cancers in women than to premenopausal cancers. Alternatively it has been suggested that the effect is age related since it is known that older women within the post menopausal group are more likely to have oestrogen receptor positive tumours and that on average, male breast cancer patients are ten years older than the females<sup>11</sup>.

Criteria for positive immunocytochemical staining for hormone receptors have changed from the presence of positive nuclei to a staining index or H score in which the product of the staining intensity grade and the proportion of positive cells (%) should be greater than or equal to 50<sup>14,19</sup>. Although 66% of our cases (6/9) showed positive staining for oestrogen receptors and 22% (2/9) for progesterone receptors, on using the staining index, posi-

tivity decreased to 44% for oestrogen receptors and 11% for progesterone receptors.

The percentage positivity in this study is lower than in most studies<sup>14-18</sup>. This can be explained by the low mean age of male breast cancers in Ghana of 48.5years<sup>3</sup>.

It would be interesting to assess the level of positivity in female breast cancers in Ghana, which appears ten years younger, mean age 38 years<sup>20</sup>.

Immunocytochemistry for oestrogen receptor is an integral part of the work up for breast cancers and the continued absence from the work up repertoire in a large part of the African continent greatly affects the choice of treatment modalities and therefore prognosis.

Five of the nine cases had lumpectomies as the first line surgical procedure and no subsequent surgical axillary lymph node dissections were identified. Preoperative diagnosis in breast tumours is essential for effective treatment and the authors will recommend fine needle aspiration cytology for the initial diagnosis before surgical intervention.

Postoperative management of males with breast cancer is very important. It is recommended that oestrogen receptor status of males with breast cancer should be determined routinely to help surgeons decide on whether to use endocrine therapy or adjuvant chemotherapy postoperatively.

The authors also recommend further research in this area to determine the long-term survival significance of oestrogen receptor status in males who develop breast cancer.

## REFERENCES

1. Bhagwande SB. Carcinoma of the male breast in Zambia. *East Afr Med J* 1972; 49: 89-93.
2. Ajayi DOS, Osegbe DN, Ademiluyi SA. Carcinoma of the male breast in West Africans and review of the world literature. *Cancer* 1982; 50: 1664-1667.
3. Akosa AB, Ampadu FO, Tettey Y. Male breast cancer in Ghana. *Ghana Med J* 1999; 33: 3-8.

4. Bloom HJ, Richardson WW. Histological grading and prognosis in breast cancer. *Br J Can* 1957; 11: 359-377.
  5. McCarty KS, Miller LS, Cox EB. Oestrogen receptor analyses: correlation of biochemical and immunohistochemical methods using monoclonal antireceptor antibodies. *Arch Pathol Lab Med* 1985; 109: 716-721.
  6. Tosi P, Bank JPA, Luzi P, Sforza V, Santopietto R, Lio R. Correlation between immunohistochemically determined oestrogen receptor content using monoclonal antibodies and qualitative and quantitative tissue features in ductal breast cancer. *Histopathology* 1987; 11: 741-751.
  7. Crichlow RW. Carcinoma of the male breast. *Surg Gynaecol Obstet* 1972; 134: 1011-1019.
  8. Ouriel K, Lotze MT, Hinshaw JR. Prognostic factors of carcinoma of the male breast. *Surg Gynaecol Obstet* 1984; 159: 373-376.
  9. Heller KS, Rosen PP, Schottenfeld D, Ashikari R, Kinne DW. Male breast cancer: a clinicopathological study of 97 cases. *Ann Surg* 1978; 188: 60-65.
  10. Thomas DB, Jimenez LM, McTierman A, Rosenblatt K, Stalsberg H, Stermbagen A et al. Breast Cancer in men: risk factors with hormonal implications. *Am J Epidemiol* 1992; 135: 734-748.
  11. Wilsher PC, Leach IH, Ellis IO, Bell JA, Eltson CW, Bourke JB, Blamay R. Male breast cancer: Pathological and immunohistochemical features. *Anti-Cancer Research* 1997; 17: 2335-2338.
  12. Ihekwaba FN. Breast cancer in men in black Africa: A report of 37 cases. *Jr Coll Surg Edinb* 1994; 344-347.
  13. Jamal S, Mush taq S, Malik IA, Khan AH, Mamoon N. Malignant tumours of the male breast –A review of 50 cases. *J Pakistan Med Assoc* 1994; 44: 275-277.
  14. Fox SB, Rogers S, Day CA, Underwood JCE. Oestrogen receptor and epidermal growth factor expression in male breast cancer. *J Pathol* Jan 1992; 166(1): 13-18.
  15. Hedit JR, Winchester DJ. Male breast cancer. *Am J Clin Pathol* 1994; 1025(1): 525-530.
  16. Weber-Chappins K, Bieri-Burger S, Hurlimann J. Comparison of prognostic markers detected by immunocytochemistry in male and female breast cancers. *Eur J Can* 1996; 32A: 1686-1692.
  17. Borgen PI, Senie RT, McKinnon WMP, Rosen PP. Carcinoma of the male breast: analysis of prognosis compared with matched female patients. *Ann Surg Oncol* 1997; 4: 385-388.
  18. Tan PY, SNG ITY. Male breast cancer. A retrospective study with immunohistochemical analysis of hormone receptor expression. *Pathol* 1997; 29:2-6.
  19. Wong SY, Carrol EDS, Eh-See Sym Sewell HF. Detection of oestrogen receptor proteins in breast tumours using an improved APAAP immunohistochemical technique. *Cancer* 1988; 62: 2171-2175.
  20. Anim JT. Breast diseases – review of surgical material at Korle Bu Teaching Hospital 1977-1978. *Ghana Med J* 1979; 18: 30-31.
-